

# Enhancement of Medical Image Visibility For Cancerous Growth by Development of Fluid-Filter Imaging Technique

PRACHI R. RAJARAPOLLU, VIJAY R MANKAR

Electronics & Telecommunication Engineering

Shri Sant Gadage Baba Amravati University

Amravati, Maharashtra, India

prachirajrapollu@gmail.com, vr\_mankar@rediffmail.com

*Abstract:-* Colonoscopy is the gold standard intended for discovering intestines cancers; nevertheless, typical colonoscopy can certainly overlook ripped growths. We focused to find out whether or not visual images of intestines ripped lesions ended up being much better by auto fluorescence image resolution as well as narrow-band image resolution graphic evaluation jointly with the latest endoscopy technique. Also, within the last several years, pathology labs began to proceed in the direction of an entirely digital workflow, using the electronic slides currently being the key element of this technique. This is achievable because of the benefits of scanning devices for whole slide imaging (WSI) which allow cost-effective generation of electronic representations of glass slides. Besides lots of benefits regarding storage as well as exploring capabilities with the image information, among the benefits of electronic slides is that they can help the application of image analysis approaches which seek to develop quantitative attributes to assist pathologists in their work. However, WSI also have some difficulties in execution and handling. Hence, such conventional method needs automation. We developed and employed to look for the targeted importance along with uncover the hest-focused graphic position by way of aliasing search method incorporated with new FFI technique.

*Key-Words:* - Colonoscopy, image resolution, endoscopy, Fluid filter imaging, anti aliasing

## 1 Introduction

As of the fact auto-focus algorithm have to be real-time, the conventional auto-focus algorithm could possibly have numerous difficulties as a consequence of increasing computations as volume of windowpane area location can vary greatly usually [1]-[3]. A definite difficulty stands out as the repeated interpolation of auto-focus receives retarded as a consequence of increasing calculations. Additionally, the likelihood linked to de-focusing of targeted image could possibly surge because of mismatch with the algorithm performance and also end result of target. Local-aliasing-sampling method is evidently applied to lessen the computation especially in medical-microscopic-dig-cam. However, inside the Local-aliasing-sampling technique, numerous accurate specifics may possibly lose in conjunction with increase in noise component [4]. As a result, the lens deviates throughout the accurate-position along with picture blur may perhaps take place. To defeat this concern, the proposed approach "FFI interpolation" evaluates every single

misplaced pixel by means of an accumulation of texture-relevant semi-local pixels when using the regularity similarity recurrently computed through a number of sections of several proportions. Particularly, implementing FFI-iteration, crucial fluid-texture pixels are involved to produce a symptoms as well as posteriori analysis, and a noticeably bilateral detailed transform is essential for regularization of unnecessary fluid/plasma layer removal from the image. Trial and error effects considered next to existing interpolation techniques confirm our approach are unable to just considerably slow up the aliasing difficulty but in addition acquire significantly better outcomes throughout a range of views just as concerning quantitative evaluation together with very subjective image quality. The introduced algorithm may be additionally utilized as a possible API for digicam image quality improvement. To summarize, employing a completely new endoscopy technique jointly with auto fluorescent imaging increased field of vision

of intestines ripped growths, corresponding to the presence attained employing chromo endoscopy. Martin, Peter R., et al. (2014) proposed investigation about how biopsy system needle delivery error affects the probability of sampling each tumor, by accounting for uncertainties due to guidance system error, image error, and irregular tumor shapes [10].

Also, as per Sonn et.al (2013), biopsy detection of cancer continues to be imperfect, restricted to both over-detection of indolent tumors and under-detection of clinically related types of cancer. Almost 50% of currently diagnosed cancer cases may be insignificant while 22% to 47% of saturation or template biopsies reveal cancer after initial negative biopsy [12].

Magnetic resonance imaging underestimates histologically identified tumor boundaries, particularly for wounds that have a high imaging suspicions score and a high Gleason score. A 9 mm treatment perimeter all around a lesion visible on magnetic resonance imaging would certainly constantly make certain treatment method of the entire histological tumor volume during focal ablative therapy [5]. However, fluid layer is present with tumor cancer growth hence it is necessary to remove aliasing effect arising due to fluid/plasma infusion. We are focusing on colorectal cancer case but the solution by FFI may be for all types of region tumor detection.

Colonoscopy is the gold standard for discovering intestines cancers. Earlier investigation has mentioned that endoscopic resection for intestines growths ends up with a 76–90% decrease [6] in the chance of acquiring intestines melanoma; even so, elements like endoscopist's insertion along with revulsion ability, cancerous growth position, and quality of colon prep, and cancerous growth depiction can lessen the potency of colonoscopy tests. The adenoma neglect rate differs through 6% to 27%. 3, 4 Ripped cancers, for example, are typically overlooked through colonoscopy, because they are complicated to discover when using the common white-light image resolution technique [7]-[9].

Despite the fact that, endoscopy gives benefits more than traditional colonoscopy, the method is more complex as well as time-consuming. Nowadays, image-enhanced endoscopy continues to be recommended [11] to further improve micro vascular comparison along with the assist in the

instant image resolution of simple patterns and also shade variances. A digital graphic improvement entails image processing algorithms. Different algorithms are already recommended according to the targets and also the modality of image resolution, which includes the one which improves the shape or fine patterns within the produced graphics, one particular focusing image comparison, one intended for color transformation and so forth. The application of existing strategies like auto resolution (AI) and also small image resolution (NI) can result in enhancements in intestines cancerous growth diagnosis rates, despite the fact that this idea is debatable [13]. These kind of combined outcomes have been acquired when using the endoscopy technique one generation before present one.

We collected existing results of the retrospective analysis for evaluation of visibility of intestines ripped tumors tested with AI as well as NI graphics. Exclusively, we focused to ascertain whether or not the analysis abilities of AI and NI were better than that of our newly developed FFI (Fluid-Filter Imaging) for the visualization of intestines ripped growths which often surrounded by uneven fluid layer. Many times, such fluid layers create visibility obstruction for doctors. Hence, many times to predict the cancerous growth at initial investigation become ambiguous.

## 2 Research Methods

Endoscopic graphics obtained from Birla Hospital patient (identity/privacy protected) at the Pune, India had been used for this current research. Existing results were obtained from physician's data that carried out AI as well as NI checkups by transitioning initial towards AI method accompanied by the NI manner. Physicians used the following equipment in this study: AI colonoscopies, light sources, and video processors.

The AI video endoscope technique is usually a new brightness process which generates real-time pseudo color graphics. The FFI technique enables instant modality transitioning through AI and NI employing a Matlab control interface. We can easily use database images captured by NI and AI without having magnification had been taken and digitally aged in electronic digital health care

records. The graphics were being determined by a highly skilled physician blinded to the present study's approaches. The FFI, NI and AI graphics for every single lesion had been delivered electronically, arbitrarily organized, and a Microsoft PowerPoint demonstration was developed. These kinds of images produced by FFI consist of fine details which could distinguish the individual or the lesion attributes.

Four skilled health professionals took part in the image assessment. The endoscopic graphics have been introduced to each one of the doctors in arbitrary order for comparability using the FFI. Doctors obtained each one of the AI and NI graphics for visibility of ripped intestines cancers based on the pursuing range: 0 (good), +2 (better), +3 (excellent in case of FFI), -2 (poor), and also -1 (very poor) [14].

The feasible highest ranking for almost any graphic had been +7, along with the probable lowest ranking had been -7. If a perception acquired a complete ranking of +7 or even more, the graphic was thought to be enhanced, a ranking in between +8 and -8 suggested no transform, along with a ranking of -10 or a smaller amount pointed out diminished presence. Here moreover analyzed the existing AI along with NI images (refer Fig.1) for further comparison with FFI output images (refer Fig. 2). Dissimilarities between images have been analyzed by visual and SPSS test. Hence, using Yamen's formula we got P-value <0. 05.

### 3 Modeling of Fluid Filter Image (FFI) Iterative Interpolation

In line with the opinion through which standard image characteristics repeated similar locations combined with the assessment of anti-aliasing in the earlier segment, we provide a continuing micro-patch interpolation strategy of anti-aliasing along with locating the high-quality image. In this article, we will take in the FFI interpolation of purely an individual iteration in addition to particular location measurement. Inside the following, we will certainly describe easy methods to assess region similarity, associated with the area analysis for dropped pixel importance calculation.

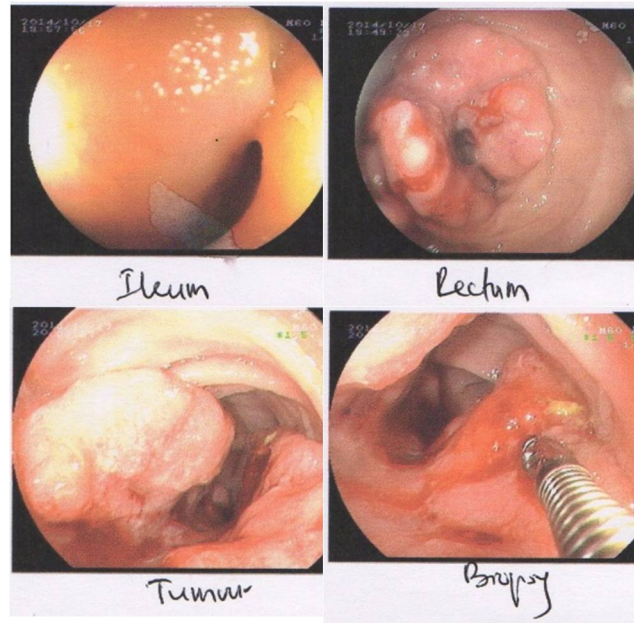


Fig. 1 Endoscopic image of AI and NI. (Source: Dr. Dharamasi Test Report, 2015)

Since mentioned, the particular aliasing artifacts nevertheless continue in this, at first, interpolated image  $\bar{I}_s$ . The task would be to locate reliable texture-relevant pixels for each and every particular misplaced pixel  $y_j$  by pixel-focused location equivalent from the grid. With this paper, so as to reduce the result connected with initially invalid interpolation, we increase the  $nl^2$  range and also advocate some sort of Window  $nl^2$  length. Within the  $l^2$  length, we bring in window  $W$  in support of estimate the  $ml^2$  length concerning the particular pixels in area  $u \cap (y_j)$  and also the similar pixels within area  $a \cap (x_j)$ , where  $a$  stands for pixel-centered region operator from the grid. Window  $W$  is dependent upon area  $a \cap (y_j)$  and as well thought as follows:

$$M_o = \begin{cases} 1, & a \cap (y_i) \text{ iff } I_t \\ 0, & \text{otherwise} \end{cases} \dots \dots \dots (1)$$

$$M_n = \begin{cases} t, & a \cap (y_n) \text{ iff } I_n \\ 1, & n \cap (y_n) \text{ iff } I_n \end{cases} \dots \dots \dots (2)$$

Here  $q$  indicates the placement of pixel in window  $W$ . While taking into consideration area  $a(y_j)$  which can be the particular positioned on  $nl^2$ , the window  $W$  is referenced as outer main focus. Or

else, the window  $W$  is identified as sub-window with next target. This procedure is going to be recurrent to recognize the smallest focus place  $n$  which is to be taken care of as  $n \cap (y_n)$  with unknown value of  $l_n$ . Immediately after confirming focus intended for window  $W$ , the curve protected area is deduced from windows location as well as remaining semi-local region pixel  $x_i$  is determined as follows:

Consider Standard deviation  $I_t * (Sd) \sigma_k$ . Similarly  $\sigma_s$  is the referenced standard deviation for  $\omega \cap (x_i y_i)$ .  $\Delta y_i$  will be the variation in between windowpane region and also covered curve. And  $\Delta y_n$  may be the lowest target pixels worked out right at the end associated with iterative working out.

With regard to every single subtracted area pixel  $\Delta y_i$  is usually as large as the entire image as well as  $\Delta y_n$  no more than the actual feasible focus pixel ideals; this might uncover just about all achievable appropriate pixels. Used, because of time difficulty, we restrict the actual research region inside the semi-local region. We also set up the sub-window that determined round the grid.

$W \otimes \sigma_k$  will be the diagonal distance associated with the center pixel as well as other pixels in a region undertaking region coordination [12]. We used  $W \otimes \sigma_k$  as linear function with the area measurement. Basically, these kinds of spatially superior pixels are considerably more reliant, using the pixels nearer to towards midsection pixel must have larger weight. Additional, as at some point explained, we will surely review windowpane as well as sub-window together with multi-scale region measurements. So that you can produce full multi-scale, we established this linear method for the targeted area.

Regular deviation refines the result involving window in addition to sub-window focus length with ultimate covering region as shown in Fig. 2. For any solitary missing pixel, function as the tolerance value to tell apart the texture-relevant pixels by means of all of the close pixels. Generally, before you start, interpolated beliefs regarding dropped pixels are usually flawed all of which deliver the dysfunction to the computation of the window dimensions. From the curiosity regarding examination, we presume the particular variation relating to begin with interpolated value connected with sub-window in addition to the

main window-value to watch any perfection connected with image capture focus with zero as well as standard deviation.

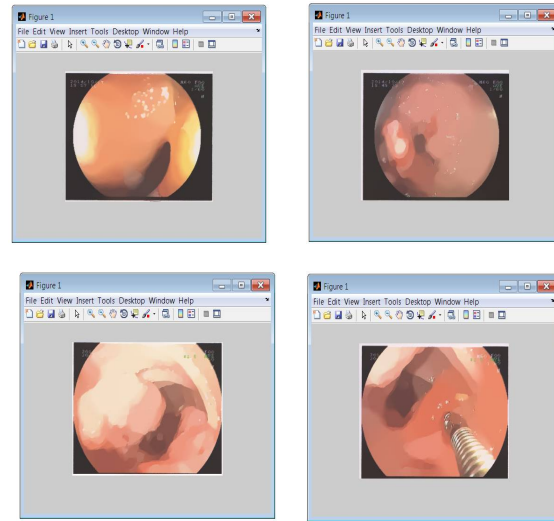


Fig. 2 Output Images of Fluid-Filter Imaging (FFI) Endoscopy Technique.

At this point, we can easily notice that window region  $W \cup a(y_i)$  is used since common region, beyond just the early interpolation until  $n(y_n)$ . All interpolated semi-local Window areas  $W \cup a(x_i)$  and sub-window area  $W \cup n(y_n)$  are usually well balanced using the regular region. As explained after using this multi-scale approach, to feature the benefits of each and every significant as well as small-scale pixel location, we got positive results caused by many preceding computations (as depicted in FFI algorithm) jointly as strategies for the scaled-down measurement variation. The actual interpolated values associated with dropped pixels one of many inputs is actually broad as well as diverse. Window region includes merely pixels and it is continuous; as a result, sub-window region can be used since the regular region to equal just about all close by primary window places it doesn't matter what input they are through.

## 4 Preprocessing FFI Algorithmic Execution

With the anti-aliasing perspective, it's appropriate to select larger region measurements so that they can uncover a lot more trustworthy pixels. The larger the region sizing, higher close by pixels are utilized since the method to locate fluid-layer-

relevant pixels as well as reduce the precise consequence related to aliasing artifacts. Nevertheless, the great textures in the regular image require scaled-down region measurements to obtain much better lively compressed facts. Normally, the artifacts may appear due to region mismatching. Nonetheless, it may be difficult to consider the actual suitable region sizing observed image getting aliasing. With this specific document, considering both of those opposite items, we suggest good recurring multi-scale interpolation solutions which replicate the actual semi-local interpolation through big to scaled-down region sizing recurrently.

### Algorithm 1: Fluid Filter Preprocessing

**Input:** Endoscopic medical image

Step-1. Initializing boundaries of window:

(a) Initial area of image point  $F_a = 0$ , Initial coordinates of window

$W_c = (0,0)$  i.e. start point of diagonal length of image point window

(b) Set step size as per standard deviation

$W \otimes \sigma_k$  and area  $a \cap (y_k)$

(c) Set  $\sigma_s$  as the referenced standard deviation of image point for  $\omega \cap (x_i y_i)$

(d) Record image boundaries by matching pixel coordinates of final window image points

(e) Store values of first window image point as a reference window image points area

Step-2. Iterative approximation of diagonal matrix:

(a) Record curve covering coordinates of parallel lines of diagonal length

(b) Deduct window image point area from curve covering extra boundary pixels

(c) Resize window image point to remaining curve

If  $Wc \otimes F_a \leq \text{curve area}$

go to step-1

else

Consider next curve for pixel coordination

3. Compute diagonal coordinates of image point window and locate boundary pixels.

4. Remove unfitted curve pixels.

5. Map next curve within diagonal pixel points within window  $W \cup cx_i$  and also  $W \cup cy_i$ .

It should be pointed out that this outcomes originating from just about all previous iterations are usually gathered collectively as inputs towards

the following little dimension version, which may be different through traditional repeating procedure. In most solitary version, presented the region sizing together with inputs which incorporated the outcomes originating from just about all previous iterations, each and every interpolated semi-local window -port region concentrated through pixel  $x_i \dots x_n$ , it doesn't matter what enter they are originating from, is actually considered towards dropped pixel  $y_i \dots y_n$  focused area.

Right after determining most colonoscopy along with related pathology studies, we ruled out reviews in which (1) there seemed to be multiple endoscopic course of action (e. g. upper endoscopy as well as colonoscopy) and/or pathology statement about the same time; (2) a similar record identified a merged upper endoscopy as well as colonoscopy process; (3) the individual identifier seemed to be lost and (4) the particular document was produced by means of computer software. The application enables a clinician to build a colonoscopy document along with pre-populated drop-down choices. Considering that the studies are actually produced in a very organized structure, we used images captured during colonoscopy (refer Fig. 1). Also, we incorporated reports produced by application (11% of most colonoscopy reviews within our sample). The rest of the colonoscopy reviews within our analyze test had been determined and also transcribed (59% of reports).

Following implementing the Matlab application for the reports, we joined the reviews to information on the individual, the physician who carried out the process along with the medical center exactly where it had been carried out. For most doctors there was entry to merely the particular subset of the colonoscopies they conducted at Birla hospital. Most of these doctors have been in specialty practice and carried out processes at Birla hospitals, and unaffiliated private endoscopy facilities.

## 5 Results and Analysis

Outcomes regarding FFI, AI and NI are revealed in Table-1 and also FFI, enhanced visibility seemed to be identified 71. 4%, close by visibility seemed to be obtained in AI 63. 1% sufficient The

likelihood of enhanced field of vision of FFI was appreciably greater than that of AI and CE graphics. The FFI scores helped for being increased, in contrast to AI and NI scores maintained to be reduced. There seemed to be absolutely no significant difference altogether field of vision scores between histopathological conclusions. There have been no major dissimilarities in interobserver understanding among endoscopic graphics (Refer Table-1).

Medical Image Technique	Visibility (%)	Doctor Remark	Performance Rating
FFI	71.4%	Clear tumor region visibility with fluid aliasing effect	Excellent for pre-surgical investigation
AI	63.1%	Traditional performance with plasma/fluid visibility around tumor	Good for surgical events
NI	27.9%	Comparatively less tumor region visibility	Good for primary tumor position investigations

Table-1: Comparative Image Visibility Analysis

Preceding work has acknowledged this variance in quality among the disadvantages of colonoscopy as being a screening process application for intestines cancer malignancy testing. Niche organizations as well as professionals have got requested vendors to consistently survey on the colonoscopy effectiveness, although couple of doctors are confirming their quality. Matlab could possibly be one methods of generating schedule exposure more prevalent.

Our final results emphasize numerous pros and cons of employing Matlab for schedule quality way of measuring employing information within image database. The important benefit of Matlab is it is monetarily possible. It becomes prohibitively costly as well as cumbersome to physically evaluate 1000s of colonoscopy studies. Yet another benefit is that Matlab enables vendors to carry on making use of normal plot whenever explaining affected individual care. The Matlab application also offers a benefit is that it is usually

effortlessly used to include modifications towards the quality actions.

Here, we in the beginning carry out trials of our method combined with various kinds regularize so as to vindicate the necessity of employing the FFI approach for image enhancement. Consequently, we analyze the recommended approach with recent FFI interpolation methods on actual medical images which are down-sampled with suggested technique in minimizing aliasing implications. Ultimately, we compared the recommended (FFI) method using existing AI and NI techniques to identify performance of FFI.

In the key research, we executed our algorithm employing FFI approach for the endoscopic images, respectively. The experimental results are confirmed in Figure-2 which in turn displays a neighborhood location of the tumorous growth without fluid or plasma inclusion, which often consisting of excessive aliasing artifacts. This means a direct result of our algorithm "FFI". We are able to quickly notice that the contour in the image pattern is restored adequately; even so the perimeters are clear, along with the pixels be observed through the interpolated pixels. However the FFI leads to the spatial smoothness, this also additionally clears the visibility for doctors. Refer Table-2 for evaluation of FFI Algorithm performance together with existing AI/NI technique [6].

Image	AI/NI Method		FFI Algorithm	
	Min	Diff	Min	Diff
Colonoscopy Image	31.43	0.711	36.32	0.842

Table-2: Comparison of FFI Algorithm Efficiency with AI/NI Method.

Eventually, the pixels are recognizable despite the fuzzy interpolated forms. Figure-2 reveals a consequence of our approach getting FFI regularization. The noticeable structures in conjunction with sharpened facets point out the advantage of our technique of FFI. In this research, we measure the performance of the fluid filter imaging protocol and that is recommended in this specific paper. We analyzed image taken by colonoscopy unit at Dr. Dharamasi Hospital



and patient was treated at Birla Hospital, Pune, India.

## 6 Discussion

Despite the fact that Intestines ripped growths are much less widespread as compared to intestines polyploidy wounds, ripped skin lesions possess higher cancerous prospective. Ripped wounds are likely, even so, to be more challenging to diagnose employing regular technique in comparison with polyploidy growths, particularly for less-experienced endoscopists. Our outcomes discovered that FFI offered excellent visibility as compared to that of AI/NI technique.

AI offered high-quality visual images of sideways scattering growths non-granular type. A number of other scientific studies have claimed that AI is fairly a good choice for differential medical diagnosis among neoplastic as well as non-neoplastic skin lesions. Even so, regardless of whether AI is really helpful for intestines cancerous growth prognosis continues to be questionable, with experts confirming combined results [9].

Also, AI colonoscopy having a transparent cover discovered much more intestines neoplasias as compared to performed NI with no transparent cover, even though carried out by means of less-experienced endoscopists [11]. The modern era of NI has been consequently formulated along with the objective of enhanced perfection, despite the fact that possible tests analyzing this declare haven't been recently released. In our analysis, there seemed to be significant difference in the standard of visual images of ripped cancers among FFI and NI.

Our results applying FFI which has a new technique found ensuring; nonetheless, there was clearly no diminished field of vision utilizing FFI in comparison with NI. This particular outcome pointed out some likelihood of FFI pre-colonoscopy ground search. Additional research is necessary to uncover the practical use of field of vision along with delectability of ripped wounds while using the new era of FFI approach. Our outcomes demonstrated that FFI technique could possibly be better than NI colonoscopy images for the recognition of ripped tumors region visibility.

## 7 Conclusion

In summary, our data revealed that FFI is a good choice for enhancing image quality throughout cases of intestines ripped cancers. In this particular paper, we've advised a FFI semi-local fluid-layer-aliasing method using FFI algorithm to obtain good quality images which can be used for pre-surgical and post-surgical primary investigations. This technique can not only obtain excellent quality of images but also lessen aliasing artifacts of images significantly so that doctors can visualize tumor region very well. As per our implementation results and doctors opinion, FFI can be very useful as an offline tool. Also concerning upcoming work, it is appropriate undertakes a technique of effectively fortifying the computational performance within our algorithm so as to entail considerably larger research region associated with anti-aliasing. And appropriate software package API may be designed to apply for real time endoscopic system development.

### References

- [1] Subramaniam, Sathya, and Manavalan Radhakrishnan. "Neural Network with Bee Colony Optimization for MRI Brain Cancer Image Classification." *International Arab Journal of Information Technology* (IAJIT) 13.1 (2016).
- [2] Jansen, Jacobus FA, et al. "Evaluation of Head and Neck Tumors with Functional MR Imaging." *Magnetic Resonance Imaging Clinics of North America* 24.1 (2016): 123-133.
- [3] Schroeder, Malte, et al. "Sunitinib treatment reduces tumor growth and limits changes in microvascular properties after minor surgical intervention in an in vivo model of secondary breast cancer growth in bone." *Journal of surgical oncology* (2016).
- [4] Pollanen, Irene, et al. "Current analysis approaches and performance needs for whole slide image processing in breast cancer diagnostics." *Embedded Computer Systems: Architectures, Modeling, and Simulation (SAMOS), 2015 International Conference on*. IEEE, 2015.
- [5] Le Nobin, Julien, et al. "Image guided focal therapy for magnetic resonance imaging visible prostate cancer: defining a 3-dimensional treatment margin based on magnetic resonance

imaging histology co-registration analysis." *The Journal of urology* 194.2 (2015): 364-370.

[6] Veta, Mitko, et al. "Assessment of algorithms for mitosis detection in breast cancer histopathology images." *Medical image analysis* 20.1 (2015): 237-248.

[7] Palmieri, Valentina, et al. "Mechanical and structural comparison between primary tumor and lymph node metastasis cells in colorectal cancer." *Soft matter* 11.28 (2015): 5719-5726.

[8] Veta, Mitko, et al. "Breast cancer histopathology image analysis: A review." *Biomedical Engineering, IEEE Transactions on* 61.5 (2014): 1400-1411.

[9] James, Alex Pappachen, and Belur V. Dasarathy. "Medical image fusion: A survey of the state of the art." *Information Fusion* 19 (2014): 4-19.

[10] Martin, Peter R., et al. "Magnetic resonance imaging-targeted, 3D transrectal ultrasound-guided fusion biopsy for prostate cancer: quantifying the impact of needle delivery error on diagnosis." *Medical physics* 41.7 (2014): 073504.

[11] Gerdes, Michael J., et al. "Highly multiplexed single-cell analysis of formalin-fixed, paraffin-embedded cancer tissue." *Proceedings of the National Academy of Sciences* 110.29 (2013): 11982-11987.

[12] Sonn, Geoffrey A., et al. "Targeted biopsy in the detection of prostate cancer using an office based magnetic resonance ultrasound fusion device." *The Journal of urology* 189.1 (2013): 86-92.

[13] Gheonea, Dan Ionuț, et al. "Quantitative low mechanical index contrast-enhanced endoscopic ultrasound for the differential diagnosis of chronic pseudotumoral pancreatitis and pancreatic cancer." *BMC gastroenterology* 13.1 (2013): 1.

[14] Tsiotsios, Chourmouzos, and Maria Petrou. "On the choice of the parameters for anisotropic diffusion in image processing." *Pattern recognition* 46.5 (2013): 1369-1381.